

THE BIOLOGICAL BULLETIN

PUBLISHED BY THE MARINE BIOLOGICAL LABORATORY

STUDIES ON VISCERAL REGENERATION IN SEA-STARS.

I. REGENERATION OF PYLORIC CAECA IN HENRICIA LEVIUSCULA (STIMPSON)¹

JOHN MAXWELL ANDERSON

Department of Zoology, Cornell University, Ithaca, N. Y.

The ability to regenerate lost parts is well developed, and well known, in sea-stars. Some forms, indeed, such as *Linckia* and *Coscinasterias*, regularly reproduce by spontaneous autotomy or fission followed by extensive regeneration of all missing portions. In general, however, asteroids utilize their regenerative capacity only to the extent of replacing relatively minor parts of the body, rays or portions of rays, lost as a result of accident or through autotomy following restraint or injury. The regenerative process is so widespread and conspicuous that it has naturally been extensively studied. Hyman (1955, p. 314) summarizes the results of several earlier investigators in the following statement: "In all species tested arms cut off at any level are readily regenerated, although the process is relatively slow. Regeneration takes place in the same manner as postlarval growth; the tip of the arm, marked by the terminal plate and tentacle and the optic cushion, appears first, and other structures are then formed between this tip and the stump in a central direction with the youngest structures just proximal to the new tip. The pyloric caeca are replaced by outgrowth from the old ones and similarly the radial water canal and radial nerve by outgrowth from the stumps of these structures."

It seems obvious that if, as has been established, the sea-star can regenerate pyloric caeca in the course of replacing an entire autotomized ray, the animal should easily be capable of regenerating them when only these organs have been operatively removed from an otherwise intact ray. Experiments to demonstrate this point have apparently not been reported, however, although studies on regenerating caeca under these conditions could be directed towards answering a group of very interesting questions related to the details of caecal regeneration. For example, it would be of interest to locate the growing point of the regenerate; is it just behind the advancing tip, as in the parietal components of a regenerating ray, or is it at the point of outgrowth from the cut stump? Hyman's statement suggests a fundamental difference between the mode of regenerative growth in the body wall and that characteristic of the caeca, radial nerve, and radial water

¹ Supported by funds from NSF Grant #G6007 to Cornell University.

vessel. Another question involves the possible role of the suspending mesenteries in guiding the growth of the regenerating caeca; it will be recalled that Kille's studies on gut regeneration in *Thyone* (1935) and Dawbin's account of the corresponding process in *Stichopus* (1949) demonstrated an intimate involvement of the mesentery-edge in early regenerative stages, and the torn mesenteric remnants may function similarly in asteroids. In addition, the presumably undifferentiated cells making up the early regenerate must at some point become transformed into the several highly specialized types of cells characteristic of the normal pyloric caecum, and the details of such transformation would be of interest. Finally, in such sea-stars as *Henricia* and its relatives the pyloric caeca are not so simple as in the asteroiids but are accompanied by elaborate flagellary pumping organs, the so-called Tiedemann's pouches, which like the caeca develop as radial branches of the pyloric stomach. If the regenerating caecum "grows out" from its cut stump, does the pouch also advance from its own stump, or is it elaborated later by differentiation from the overlying caecum?

Answers to questions such as these, and the details of the regenerative processes, were sought in a series of experiments involving operative removal of the pyloric caeca in several species of sea-stars. The results to be reported here are those obtained in a somewhat limited number of operations performed on *Henricia leviuscula*, following which the experimental animals were observed for a maximum of eight weeks. This series, though small and of brief duration, is sufficient to provide basic information on several of the general questions involved, and discussion of these results will provide a background for subsequent accounts dealing with other species and other portions of the digestive system.

These studies were begun during tenure of a John Simon Guggenheim Memorial Fellowship in 1958-59, at the Hopkins Marine Station of Stanford University, Pacific Grove, Calif. The generosity of the Guggenheim Memorial Foundation, and the hospitality and assistance of the Director and staff of the Hopkins Marine Station, are gratefully acknowledged.

MATERIAL AND METHODS

Small to moderate-sized specimens of *Henricia leviuscula* (radius averaging about 2 cm.) were collected beneath stones in the intertidal area at Point Piños, near Pacific Grove, Calif. Stocks of these animals were maintained in running sea-water in one-gallon jars fitted with escape-proof collars of plastic screening. Although offered a variety of food, the specimens were never observed to feed; they remained in apparently vigorous condition, however, for periods of two months or more. The suggestion has been made elsewhere (Anderson, 1960) that *Henricia* is capable of subsisting on suspended particulate matter.

Selected specimens were immobilized by soaking for 15 minutes in $MgCl_2$ solution (8% in tap water). Using iridectomy scissors, a median longitudinal incision was made through the aboral body wall of one ray. Through this incision the paired pyloric caeca of the ray, together with their associated Tiedemann's pouches, were removed by grasping the caeca in watchmaker's forceps and either tearing or cutting their mesenteric attachments inside the aboral body wall, finally transecting the pyloric ducts and Tiedemann's pouches as near as possible to their

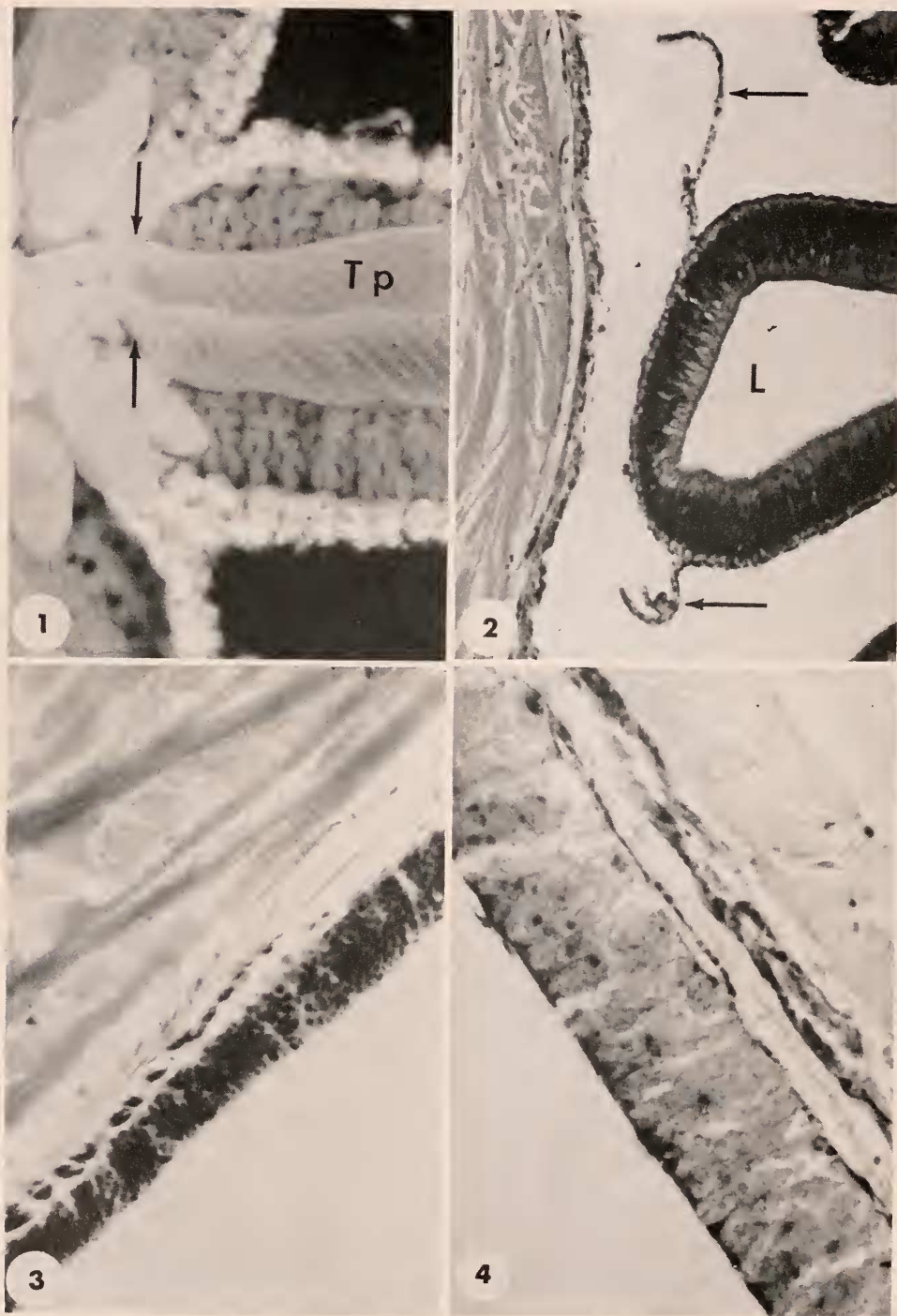
proximal origins from the pyloric stomach (Fig. 1). Identification of individual specimens was facilitated by performing the operation on different rays, numbered consecutively from the madreporite, by clipping off the distal tips of different combinations of rays, and by noting distinctive features of the highly variable color patterns of different individuals.

Returned to running sea-water, the animals recovered rapidly from the effects of the magnesium treatment and of the operation. Without suturing or other assistance the edges of the incision gradually approached each other, beginning proximally, and one week after the operation the wound was usually closed by a thin and rather delicate white web of connective tissue. By the end of the second postoperative week healing was well advanced, and the site of the incision was recognizable only by a persistent furrow in the body wall, by its somewhat lighter color, and by the absence of papulae and spines. These differences gradually became less conspicuous during following weeks, but the furrow was still noticeable after four weeks.

Internal events could be checked only by sacrificing the animal. At weekly intervals, selected individuals were again soaked in $MgCl_2$ solution to prevent movement, and all rays except the operated one cut off near the disk. By making an "equatorial" incision through the body wall all around the animal, and cutting the digestive tract across at the junction between cardiac and pyloric stomachs, oral and aboral portions of the body were separated. The aboral portion, bearing the pyloric stomach and any regenerated parts of the caeca in the operated ray, was inverted and pinned out flat, face up, in a small wax-bottomed dissecting pan, using fine glass needles. After gross examination, the preparation was sketched or photographed, flooded with Helly's fluid, covered, and allowed to fix and harden for several hours. At the end of this preliminary fixation period, the specimen was trimmed and the significant portions transferred to a vial of Helly's fluid for an additional 24 hours' fixation. The tissue was then washed overnight in running water and placed in a decalcifying solution (disodium EDTA, 5% aqueous) where it remained for one week. The specimen now consisted of the delicate regenerating parts of the caeca, attached to and supported by the tough, decalcified adjacent portion of the aboral body wall. This was dehydrated and embedded in paraffin by standard technics and $7\ \mu$ serial cross-sections prepared. The sections were stained with Mallory's phosphotungstic acid hematoxylin (PTAH), Harris' hematoxylin and fast green, or a periodic-acid-Schiff (PAS) routine followed by fast green and Weigert's acid-iron-chloride hematoxylin. The PTAH technic was particularly useful in demonstrating flagellary basal bodies and intracellular secretory granules, as well as in distinguishing between muscle and collagenous tissue; the PAS routine revealed membranes and mucous gland cells.

RESULTS

The experiments and observations, which followed the changes in operated animals for a maximum of only 8 weeks, clearly demonstrated that even in this relatively brief period some progress is made toward regenerative replacement of extirpated pyloric caeca. The process of regeneration involves an orderly, consistent series of events which may now be explored and described; before



FIGURES 1-4.

proceeding to this, however, it will perhaps be helpful to review briefly the normal anatomy and relationships of the pyloric caeca and adjacent structures.

The body wall is covered internally by the parietal peritoneum, a generally flattened, cuboidal, flagellated epithelium in which only occasional cells contain accumulations of granules staining intensely with PTAH. Along two parallel lines above each pyloric caecum this layer rises to form the paired mesenteries by which the caecum is suspended from the aboral body wall. Although these mesenteries consist fundamentally of the standard two mesothelial layers separated by mesenchyme, it is noteworthy that in *Henricia* they are not continuous sheets but form a highly fenestrated, weblike tissue (Fig. 2). It is these suspensory webs that were cut or torn apart in the operative removal of the pyloric caeca. The mesothelium of the mesenteries is continuous with the visceral peritoneum, which forms the outermost layer clothing the pyloric caecum and its appended Tiedemann's pouch. Over these organs the mesothelium is markedly flattened, and the nuclei of its flagellated cells are peculiarly bean-shaped. Figure 2 shows the relationships between the median duct of a caecum, the paired mesenteric webs, the parietal peritoneum, and the overlying aboral body wall. Further anatomical and histological details of the pyloric caeca need not be described here; characteristics of the tissues involved and the distribution of individual cell types have recently been elucidated (Anderson, 1960). It should perhaps be noted, however, that the epithelium of the median caecal duct contains an extremely high concentration of zymogen cells packed with secretion droplets demonstrable by the PTAH technic; this characteristic is of significance as a recognition feature for remnants of the duct in regenerating tissues.

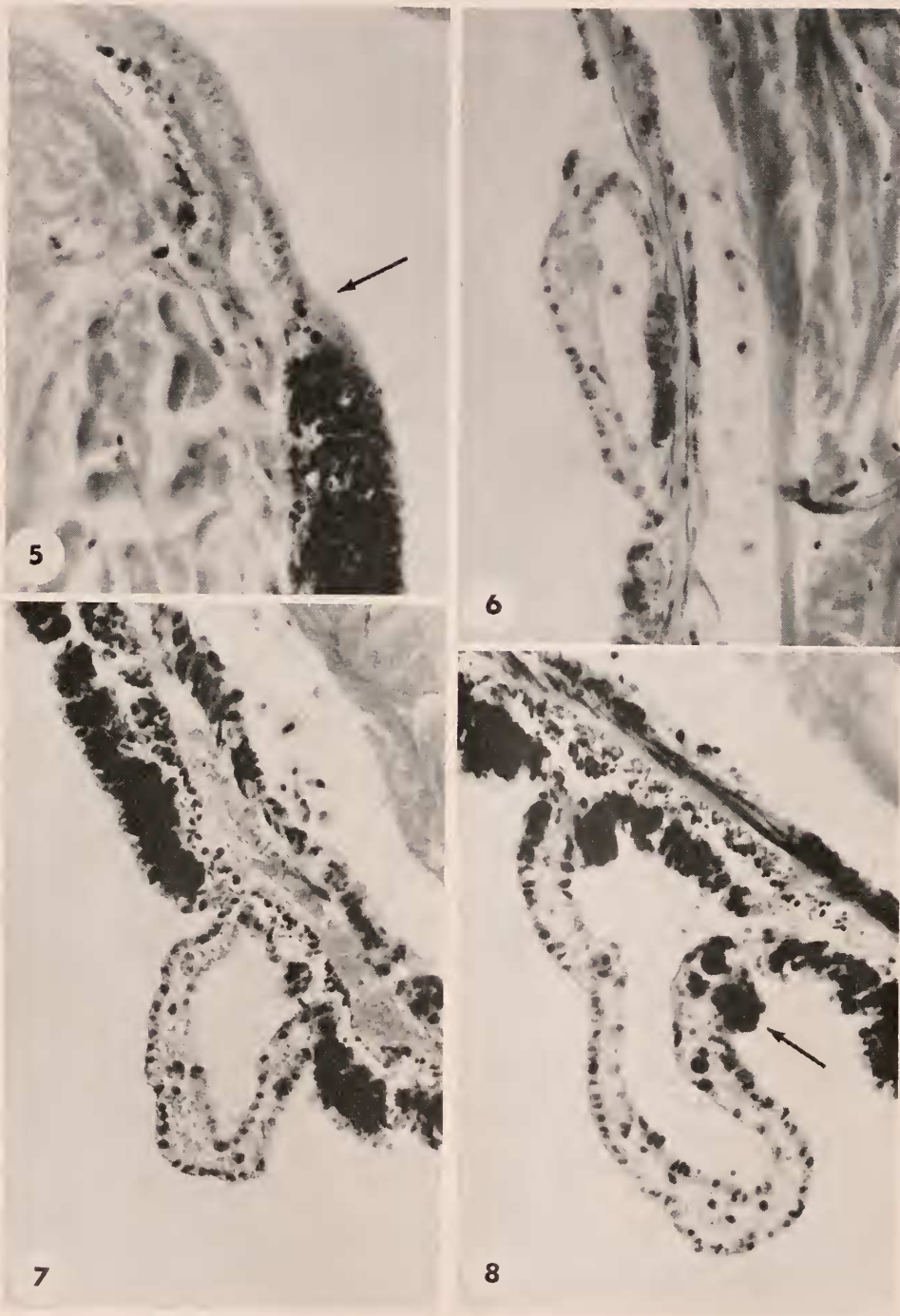
Following operative removal of the pyloric caeca, the first week is marked only by early stages in the healing of the incision, with no noticeable internal changes. At the close of the second postoperative week, however, although there are no conspicuous signs of caecal regeneration, sections reveal that preliminary events are in progress. One of these consists of a very marked hypertrophy of the parietal peritoneum; its normally flattened, cuboidal cells have now become several times taller than usual and are packed with coarse spherules (Fig. 3). These cytoplasmic inclusions are PAS-negative (Fig. 4), and in sections stained with Harris' hematoxylin and fast green they are neither basophilic nor markedly acidophilic; they do, however, stain intensely blue-black with PTAH. In staining behavior, as in shape and size, the spherules resemble those occasionally found in scattered peritoneal cells in the normal animal, as well as the abundant secretory

FIGURE 1. Dissection of a fresh specimen, viewed from oral aspect, showing proximal portions of intact digestive organs in one ray. Tp = Tiedemann's pouch; arrows indicate approximate level at which the organs were severed in operative removal. Approximately 10 \times .

FIGURE 2. Cross-section of ray showing relationships of body wall, mesenteries, and pyloric caecum. Aboral body wall at left; L = lumen of median caecal duct; arrows indicate portions of the paired suspensory mesenteries, which are not continuous sheets but interrupted webs. Harris' hematoxylin, fast green. 230 \times .

FIGURE 3. Hypertrophied, granule-packed peritoneum in a regenerating specimen, fifth postoperative week, at a distal level in the ray; compare with normal peritoneum in Figure 2. Phosphotungstic acid (PTA) hematoxylin. 460 \times .

FIGURE 4. Taller hypertrophied peritoneum at a more proximal level in a specimen after four weeks' regeneration. Periodic-acid-Schiff, fast green, Weigert's hematoxylin. Note that the cytoplasmic granules are PAS-negative, while small areas in the free ends of the cells react strongly with the Schiff reagent. 460 \times .



FIGURES 5-8.

granules normally present in zymogen cells of the caecal epithelium. It is to be noted that hypertrophy of the peritoneum is confined to the general coelomic lining and never involves the mesothelial cells which form the lining of the dermal branchiae; there is an abrupt transition where the general parietal peritoneum joins the mesothelium at the base of each papula (Fig. 5).

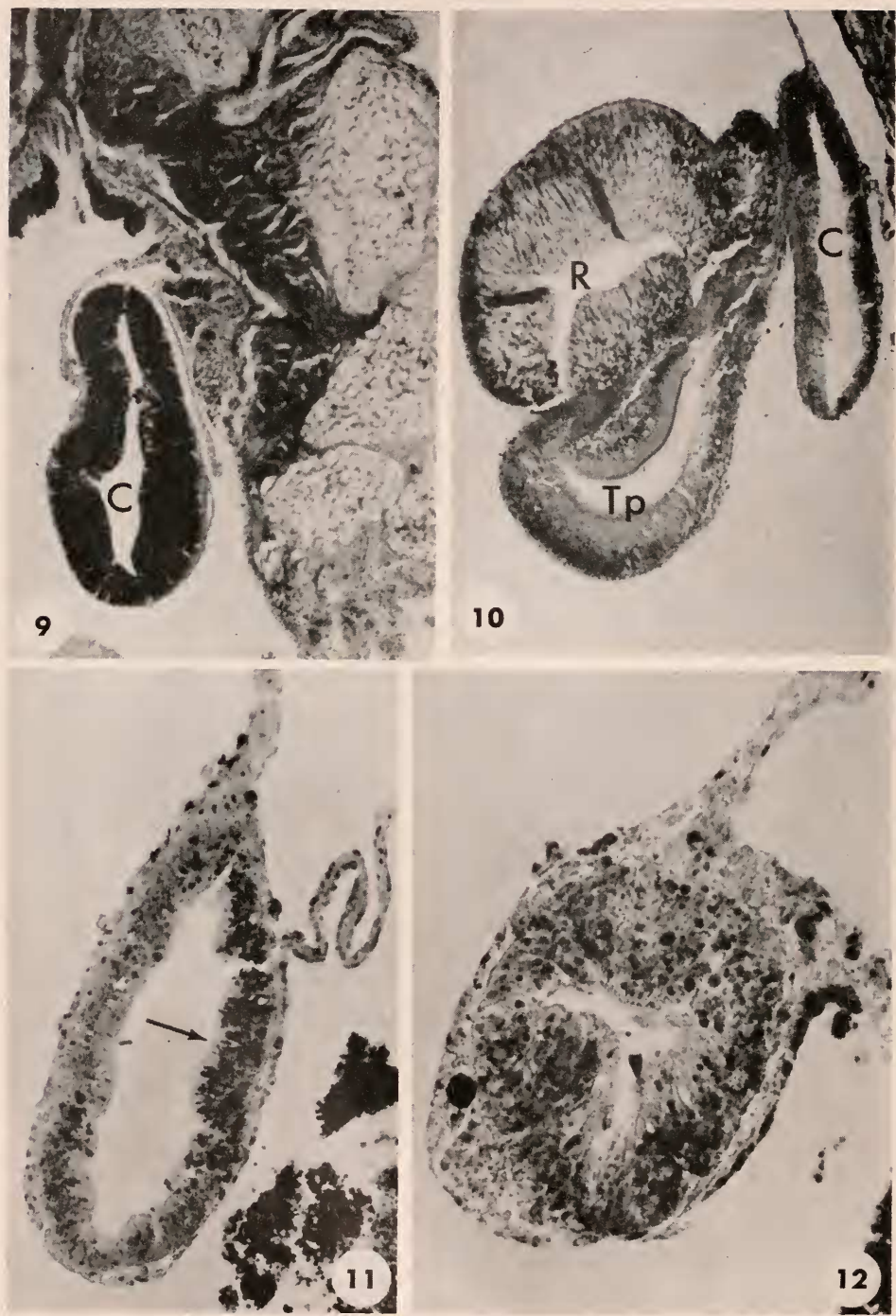
The other notable change at the close of the second postoperative week involves the fusion of the remnants of the paired caecal mesenteries. The members of each pair have become attached to each other by their free edges to form a mesenteric tunnel, which distally is small and flattened (Fig. 6) but proximally becomes progressively taller as it approaches the stump of the caecum (Figs. 7, 8). Unlike the fenestrated, weblike mesenteries noted in the normal animal, the regenerating mesenteric tunnels clearly consist of continuous mesothelial sheets enclosing between them a loose mesenchymal layer. Proximally, the mesenteric tunnels join the suspensory mesenteries of the transected pyloric ducts remaining from the operation. Throughout their length, the mesothelia of the tunnels are continuous with the parietal peritoneum. The fact that, as seen in Figure 8, granule-filled peritoneal cells are found partway up the side of a tunnel suggests that the mesenteries incorporate cells from the general peritoneum at their bases. The mesenchyme enclosed between the mesenteric sheets communicates basally with the subperitoneal muscular and collagenous layers of the body wall. It consists of a loose, fibrous meshwork containing large cells, many of which contain deeply-staining cytoplasmic inclusions.

Proximally, the stumps of the transected pyloric ducts have, in effect, simply rounded up and healed over. In one case (Fig. 9) the zymogenic epithelium characteristic of the roof of the pyloric duct has formed a tube which extends a short distance beyond the beginning of the mesenteric tunnel before ending blindly. In none of these proximal remnants are there indications that new growth has occurred in the two weeks since removal of the caeca.

Grossly examined, the single specimen opened three weeks after caecal extirpation shows that the proximal stumps remaining after the operation have produced a short outgrowth extending in one of the mesenteric tunnels. Sections of these regions reveal that the remnants are still histologically recognizable as parts of Tiedemann's pouches and the radial reservoirs of the pyloric stomach, twisted and distorted (Fig. 10). Aborally, a tubular structure separates from the proximal stump (Fig. 11) and proceeds distally, pushing its way through the mesenchyme at the summit of a mesenteric tunnel, gradually tapering, becoming a solid rod of cells, and finally terminating after a course of a few millimeters. The second mesenteric tunnel separates from the basal remnant and extends into the ray without an epithelial tube or rod at its summit. Near its proximal end, the epithelial tube that is present shows histological characteristics reminiscent

FIGURE 5. Section showing sharp transition (arrow) between hypertrophied general peritoneum and the mesothelium lining a dermal branchia, in a specimen after 3 weeks' regeneration. PTA hematoxylin. 460X.

FIGURES 6, 7, 8. Progressively more proximal cross-sections of the mesenteric tunnel formed in a two-week postoperative specimen by fusion of the free edges of paired suspensory mesenteries. Note that the mesenteries now constitute continuous mesothelial sheets separated by loose mesenchyme. The flat distal tunnel becomes progressively higher at proximal levels. Arrow (Fig. 8) indicates a granular peritoneal cell in mesothelium of the tunnel. All PTA hematoxylin. 460 X.



FIGURES 9-12.

of the median duct of the pyloric caecum, especially in the concentration of cells resembling zymogen cells in its roof (Fig. 11). It is to be noted, however, that these epithelial cells and the crowded spherules they contain are disorganized and preserve none of the very regular orientation normally found in the roof epithelium of the median duct. In the regenerate, these cells appear to be resorbing their secretion, rather than producing it as in the normal animal. Following the sections distally, one finds that the tube becomes progressively smaller and more nearly cylindrical, and the lumen steadily decreases in size. In these regions the nuclei of the epithelial cells are crowded basally, leaving the apical ends of the cells relatively clear (Fig. 12); there are some indications here of the development of a brush border and other apical specializations, as in the normal caecal epithelium. The terminal, rodlike portion of the outgrowth, beyond the point at which the lumen disappears, is composed of packed, spherical, largely undifferentiated cells. A few cells at this level contain large mucous vacuoles, but there are no indications of other types of secretory activity. The sections show clearly (Figs. 12, 13) that in three weeks the regenerative process has produced only an epithelial outgrowth advancing in the mesenchyme between the mesothelial sheets forming the mesenteric tunnel. As shown in Figure 14, this mesenchyme contains numerous cells that appear to be undifferentiated amoebocytes, some with cytoplasmic inclusions of various kinds. While the line of separation between the epithelial core of the regenerate and the surrounding mesenchyme is clearly distinguishable, no "basement membrane" (= collagenous layer; see Ferguson, 1960) has been laid down. In fact, none of the normal subepithelial components of the caecum, such as the nerve plexus layer, muscular layers, etc., are yet represented in the three-week specimen. Beyond the distal end of the rodlike outgrowth, the mesenteric tunnel continues a long distance into the ray; it here appears similar in all respects to the tunnels noted as the only regenerative products in the two-week specimen (Fig. 15).

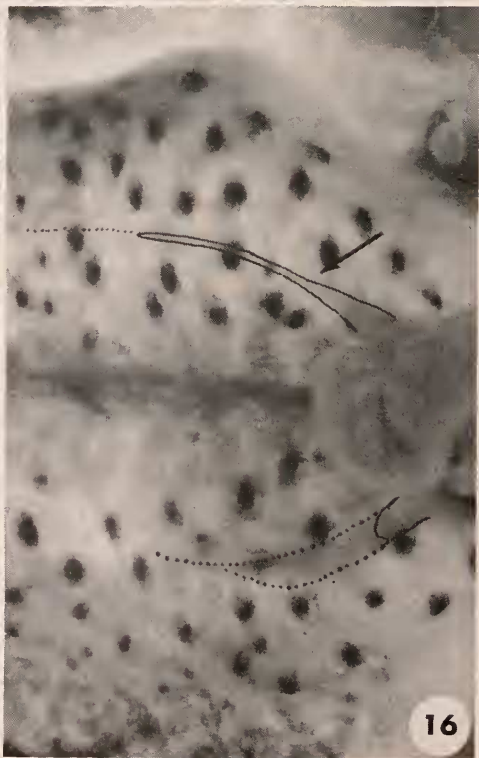
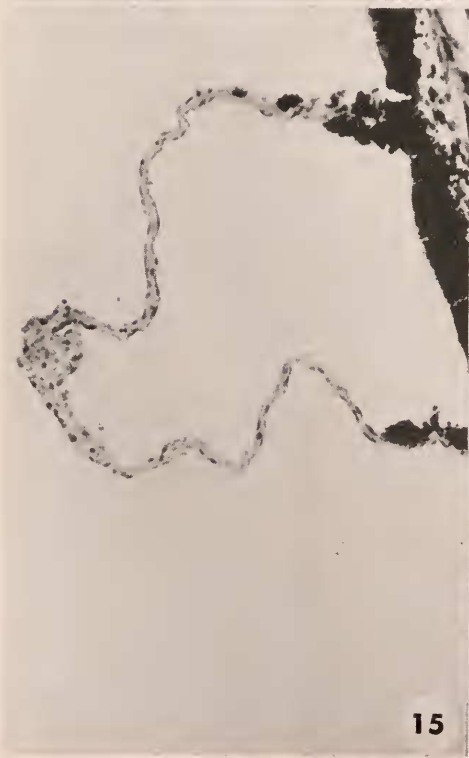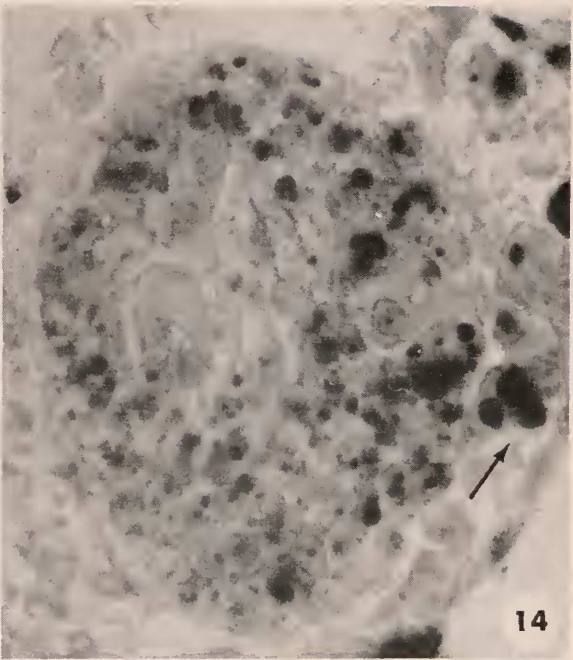
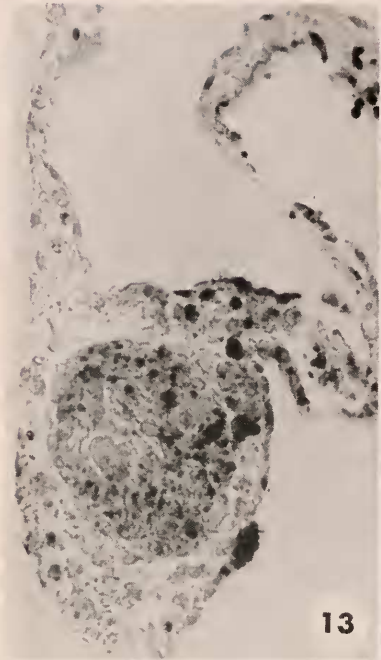
An overall view of conditions in the operated ray of a four-week specimen is shown in Figure 16. Basally, the remnants of the paired Tiedemann's pouches and radial reservoirs have shrunk and adhered to one another, forming a single twisted fusion mass. From the mesenteric supports of this basal structure two mesenteric tunnels lead outward into the ray. One of these (the lower, in the photograph) is small, flat, rather poorly developed, and appears empty except as it is associated with a short, blunt projection from the corner of the fusion mass.

FIGURE 9. Cross-section of healed stump of median caecal duct (C), two-week specimen. Aboral body wall at upper right. Note the typical high concentration of zymogen cells in the epithelium of the duct. PTA hematoxylin. Approximately 75 \times .

FIGURE 10. Cross-section of regenerating specimen at proximal level, three weeks postoperative. At R and Tp, recognizable remnants of radial reservoir and Tiedemann's pouch are indicated. Above these, C denotes the tubular caecal regenerate at the level where it begins to separate from the proximal remnants of the operated organs. This tube arises aborally, from the stump of the median caecal duct. PTA hematoxylin. Approximately 75 \times .

FIGURE 11. Cross-section of the same three-week tubular regenerate at a more distal level. Note concentration of disorganized zymogen-cell remnants in roof of tubule (arrow); mesenteric attachments at upper right. PTA hematoxylin. 230 \times .

FIGURE 12. Cross-section of the same tubular regenerate (three weeks postoperative) still more distally. The lumen is poorly developed at this level, but the epithelial cells show conspicuous signs of differentiation. Note the sharp line of demarcation between the bases of the epithelial cells and the surrounding mesenchyme. PTA hematoxylin. 460 \times .



FIGURES 13-16.

The other, however, is occupied by a tapering extension from its corner of the mass, and this accompanies it for a considerable distance into the ray. The relationships of these parts are best understood by studying serial cross-sections of the material. The histological characteristics of the basal fusion mass remain recognizably those of the radial reservoirs and Tiedemann's pouches; the less well developed of the two mesenteric tunnels is observed to lead off from its corner of this structure and almost immediately to become flattened against the aboral body wall. Throughout its subsequent course it remains undifferentiated, resembling very closely the two-week distal tunnel shown in Figure 6.

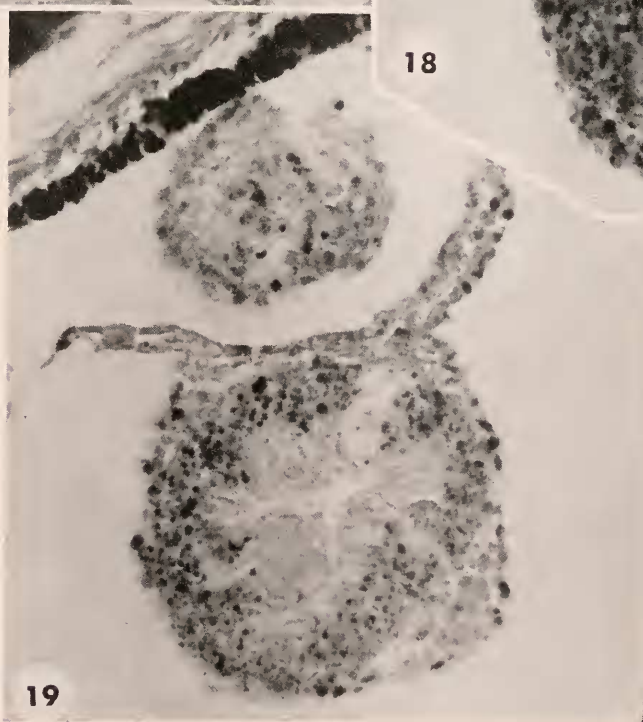
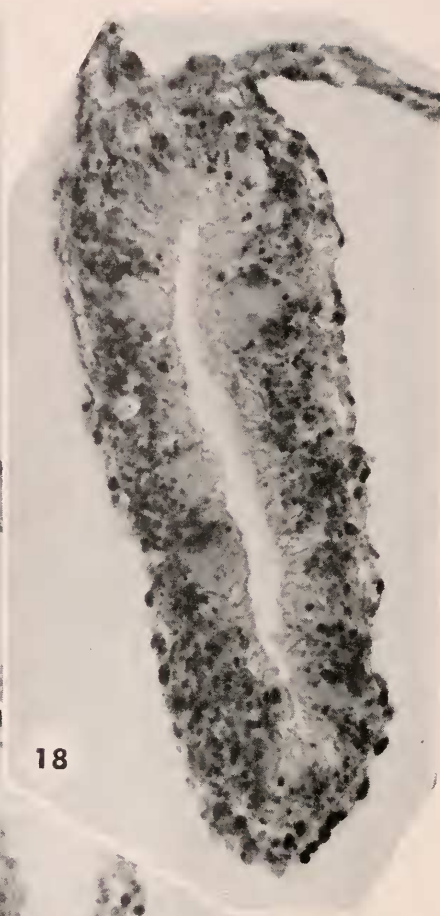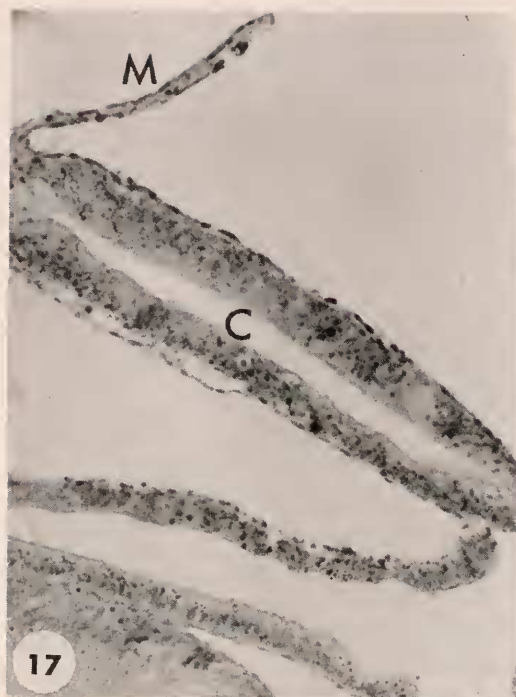The outgrowth accompanying the second tunnel is a tubular structure arising from the most aboral part of the basal remnant. For a short distance on its oral side its layers are continuous with those of the Tiedemann's pouch remnant lying below it, but judging from its point of origin as well as from its histological characteristics, this tube clearly represents an outgrowth from the transected median duct of the corresponding pyloric caecum. As Figure 17 shows, the origin of this tube is similar to that of the three-week regenerate; at four weeks, however, the epithelium contains no significant concentrations of the deeply-staining secretory material characteristic of the normal median-duct epithelium and noted aborally in the three-week specimen (compare Figs. 11 and 17). In other respects the epithelium at this proximal level has undergone considerable differentiation (Fig. 18). Mucous gland cells are well represented, and the majority of the ordinary epithelial cells have begun to assume more of the normal columnar aspect, with nuclei crowded towards their bases and the distal ends showing signs of incipient flagellum and brush-border differentiation. It is noteworthy that the tubular regenerate in this proximal, most advanced level is tall and narrow; this suggests that the deepening of the radial organ, bringing about separation of the oral, outflowing flagellary currents from the aboral, inflowing ones, has already begun in the fourth postoperative week. This deepening has, to be sure, advanced only a limited distance in the regenerate; beyond the approximate point indicated by the arrow in Figure 16 the tubule tapers to a cylindrical cross-section, and progressively more of the regenerate comes to be occupied by epithelial cells as the lumen gradually disappears. At this level (Fig. 19) the four-week regenerate is practically identical in composition and appearance with the more proximal levels of the three-week regenerate (compare Fig. 12); the cells are relatively undifferentiated, crowded basally but elongating distally, and numerous mucous goblets are present. Beyond the point at which the lumen disappears there is a

FIGURE 13. Cross-section of three-week regenerate at still more distal level, where the advancing rod has not yet developed a lumen. The distinction between epithelial outgrowth and the surrounding mesenchyme is clear. PTA hematoxylin, 460 \times .

FIGURE 14. Same section as in Figure 13, somewhat enlarged. The clear intracellular areas in the mass of epithelial cells are mucous secretions. Arrow indicates a clump of amoebocytes with coarse granular inclusions. PTA hematoxylin, 1100 \times .

FIGURE 15. Cross-section of mesenteric tunnel in three-week regenerate beyond the level reached by the advancing epithelial rod. PTA hematoxylin, 230 \times .

FIGURE 16. Dissection of fresh specimen showing conditions at the close of the fourth postoperative week; center of disk is to the right. At the base of the ray, note the twisted mass representing fused remnants of Tiedemann's pouches. The extent of the two regenerating caeca is indicated by inked outlines; the mesenteric tunnels are dotted. Arrow indicates the point at which the tall, narrow regenerate tapers to a simple cylindrical tube. Approximately 15 \times .



FIGURES 17-19.

short, solid, rodlike region of the outgrowth similar in all respects to the three-week level shown in Figure 13; past its termination, a well-developed mesenteric tunnel can be traced a considerable distance out into the ray.

One further observation on the four-week specimen is of significance: the regenerate does not contain, at any level, recognizable representatives of the normal subepithelial components of the caecum. The space between the base of the lining epithelium and the covering visceral peritoneum is still occupied only by loose mesenchyme containing amoebocytes.

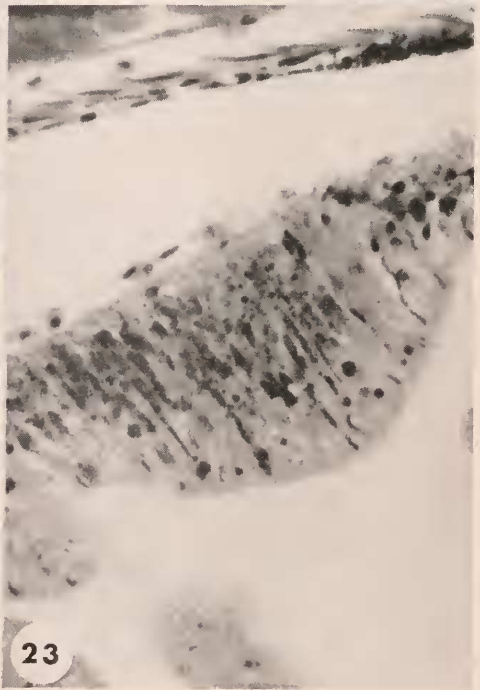
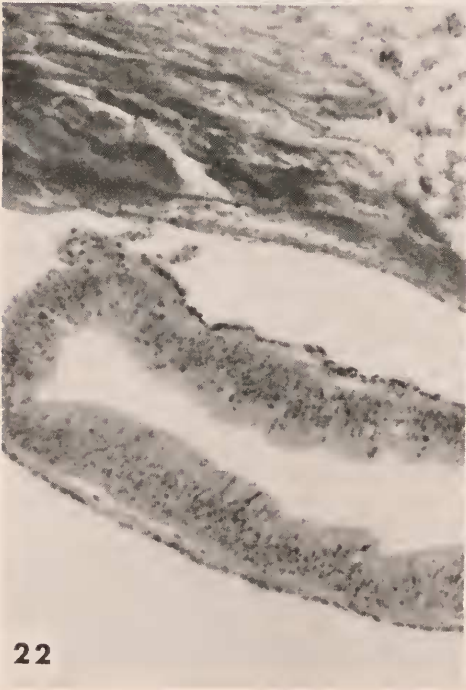
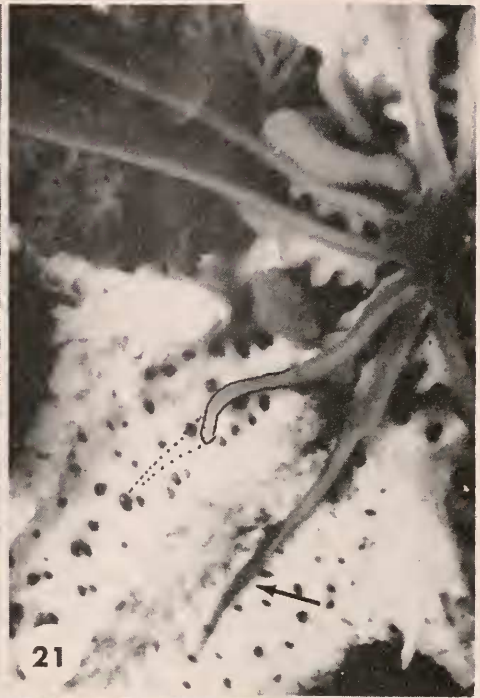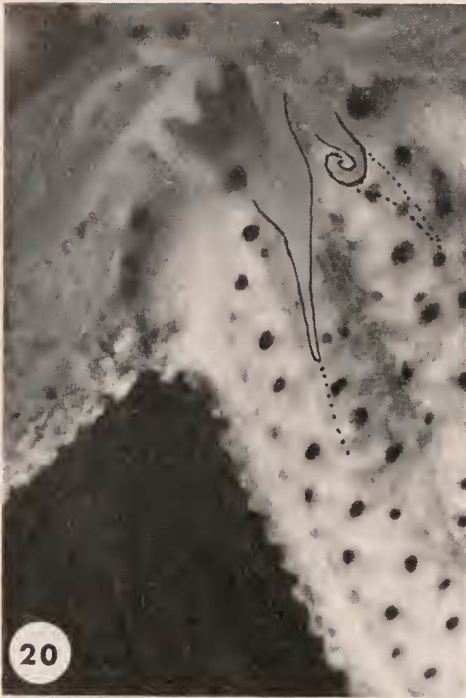At six weeks (Fig. 20) the regenerate is larger and longer than at four. In this specimen, one of the two regenerating tubes was unfortunately damaged in preparation, and the tissue was not sectioned. It is apparent from general examination, however, that although the damaged tube was not as long as the intact one it was relatively well developed. Thus, unlike the situation in specimens sacrificed earlier, both of the caeca were being replaced in this six-week animal, one perhaps more slowly than the other. In other respects appearances indicate that regenerative progress at six weeks is about what might have been predicted from study of the earlier stages.

Figure 21 shows the regenerating caeca in the most advanced of the specimens operated in this series, sacrificed eight weeks after caecal extirpation. The paired stumps of Tiedemann's ducts and the radial reservoirs have not healed together as in the four-week specimen; rather, each has retained its integrity and has produced an extension into the ray. Again, one of these is somewhat in advance of the other. The regenerating structures take their origins from the aboral parts of the basal remnants, although their layers are proximally continuous with those of the Tiedemann's ducts as well. Histologically, this eight-week specimen shows several interesting and significant features; attention will be focused on the better-developed of the two regenerates. Near its origin, this structure is a tall and narrow tube, with a lumen bounded by markedly normal-looking columnar epithelium (Fig. 22). Proximally, the roof of the tube shows a considerable concentration of cells containing strings of zymogen granules, scattered among the typical attenuated epithelial cells (Fig. 23). Close study of this region shows that the epithelium is flagellated, as in the normal caecum. The floor of the tubular regenerate is occupied by crowded cells with long flagella, forming a gutter-like structure. In these cells, and in those lining the sides of the tube, concentrations of moderately fine PAS-positive droplets are localized. Such droplets stain similarly to the contents of mucous gland cells, which are also numerous in this region, and may represent precursors of mucous secretions. The differential concentration of zymogen cells aborally, and of mucous-related and current-producing cells orally, suggests re-establishment of the normal regional

FIGURE 17. Section at proximal level in four-week regenerate. M = one of the mesenteric sheets; C = caecal regenerate. At lower left a portion of the basal remnant of Tiedemann's pouch. PTA hematoxylin. 230 \times .

FIGURE 18. Section at a more distal level in four-week regenerating caecum; mesenteric attachments above. Note the considerable cellular differentiation in the epithelial lining, with occasional mucous goblets (clear areas) and basal concentrations of nuclei. No subepithelial components (muscle, connective tissue, etc.) have yet appeared. PTA hematoxylin. 460 \times .

FIGURE 19. Four-week regenerate sectioned at a level just beyond the extent of the lumen; compare with section of three-week regenerate in Figure 12. Mucous glands well represented. A fragment of debris is trapped in the mesenteric tunnel above the regenerate. PTA hematoxylin. 460 \times .



FIGURES 20-23.

specializations of the caecum and its pouch. In these more advanced proximal regions a definite subepithelial collagen layer is now recognizable, and the characteristic network of muscle fibers is also in evidence. These layers are not fully developed, and there are no clear indications of a nerve plexus layer, but conditions here are much advanced when compared with those in the four-week regenerate. The visceral peritoneum is thin and flattened, and its nuclei are again normally bean-shaped. Notably, the hypertrophy of the parietal peritoneum has subsided, and there are only scattered areas in the vicinity of the mesenteries, as in Figure 23, where cells of this layer are still charged with deeply-staining spherules.

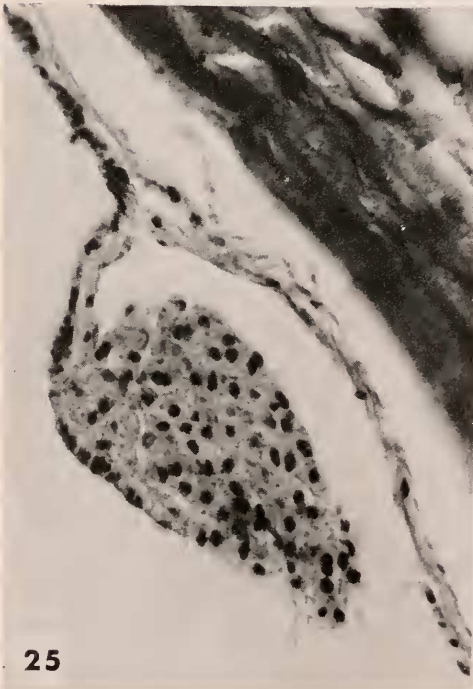
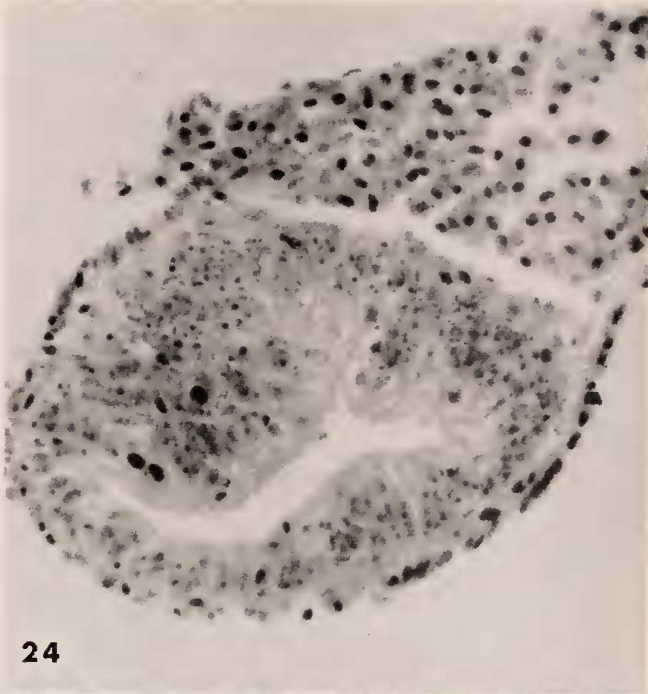
At progressively more distal levels the characteristics of the eight-week regenerate show gradual changes toward those of less advanced stages. Approximately halfway between base and tip, for example, the shape of the epithelial tube has become more nearly cylindrical, and its lumen is relatively restricted. The cells forming the tube are on the average tall and well differentiated, but no zymogen cells are in evidence. There appears, however, as in Figure 24, a noticeable distinction between the thick-walled roof and the thin-walled floor of the tube at this level. Subepithelial components do not extend to this point in the regenerate. Even farther distally, the lumen disappears altogether, and the regenerate is represented only by a solid, rodlike outgrowth in the mesenchyme of a mesenteric tunnel. Beyond the end of this solid rod the tunnel continues for some distance, very similar in essential features to tunnels observed earlier. One aspect of this specimen is noticeably different: the distal, tapering portion of the longer regenerate appears to be surrounded by a diffuse, granular mass which in the living specimen was colored a vivid orange (Fig. 21). In sections, this mass is revealed as consisting of an extensive accumulation of coelomocytes, apparently trapped inside the mesenteric tunnel (Figs. 24, 25). The relationship between this coelomocyte clot and the tissues of the regenerate and its supporting tunnel is so close as to suggest that coelomocytes may have contributed to the cells incorporated in the regenerating tissue. Far distally, beyond the region of coelomocyte accumulation, the mesenteric tunnel extends as a simple, low structure identical in appearance and composition to the tunnels observed, for example, in the two-week specimen (compare Figs. 6, 26). At this distal level it will be noted that the parietal peritoneum retains considerable patches of hypertrophic cells packed with granules similar to those found more proximally in younger stages.

FIGURE 20. Fresh dissection of specimen at close of sixth week of regeneration. The tapering, tubular caecal regenerates are outlined in ink, with mesenteric tunnels dotted. The curled regenerate was damaged in the dissection. Note persistence of scar in the area of the healed incision (between the two regenerates). Approximately 15 \times .

FIGURE 21. Fresh dissection of specimen after eight weeks' regeneration; one of the regenerates and its mesenteric attachment emphasized by inked outline. The levels at which the organs were originally severed are clearly shown as the origins of the somewhat smaller regenerating tubes. Arrow indicates concentration of coelomocytes described in the text. Approximately 10 \times .

FIGURE 22. Cross-section at proximal level through eight-week regenerate; note normal appearance of the epithelium. The tubule is tall and narrow, with its roof at left; it has swung to the right in processing. PTA hematoxylin. 230 \times .

FIGURE 23. Details of epithelium in the roof of eight-week regenerate, showing accumulation of apparently functional zymogen cells. The epithelium is flagellated, and subepithelial collagenous and muscular layers are present at this level. PTA hematoxylin. 460 \times .



FIGURES 24-26.

DISCUSSION

The experiments described here establish the fact that within the otherwise undamaged ray of a sea-star, after healing of the operative incision, excised pyloric caeca are replaced by regenerative processes following a consistent pattern. As pointed out by Hyman (1955) in the passage quoted earlier, when an entire ray is being regenerated the specializations characteristic of the distal extremity are produced first. Just proximal to the newly formed tip lies a localized zone of growth which moves outward, pushing the tip ahead of it and generating replacement tissues behind it in the elongating ray. Thus, as clearly demonstrated in the work of Schapiro (1914) and Zirpolo (1921), the oldest, first-differentiated region of a regenerating ray is the distal tip; immediately adjacent to this lies the least-differentiated region, constituting the zone of growth, and between this zone and the base of the regenerating ray there is a gradient of increasing age and differentiation in the tissues. These facts have been demonstrated for the parietal portions of the ray; in contrast, the present studies show that in the regenerating pyloric caecum of *Henricia* there is no differentiated tip region proceeding distally in advance of a growth zone. The tip of the regenerating caecum, at the extremity of the solid rod of cells pushing outward in the summit of the mesenteric tunnel, is composed of the least-differentiated and presumably youngest cells, and the gradient of increasing differentiation begins immediately behind this tip. The advancing tip of the rod thus appears to constitute, or at least to include, any zone of growth that may be present in the caecal regenerate. To this extent, then, the growth processes involved in replacing excised visceral components of the ray differ markedly from those producing parietal or body-wall portions. It seems reasonable to infer that these differences prevail also in the normal growth of the sea-star and in situations involving regeneration of entire rays following autotomy.

The remnants of the mesenteries are evidently of great significance in the replacement of excised pyloric caeca. In no case have I observed regeneration of a caecum in the absence of the characteristic preliminary changes involving the suspensory mesenteries. The initial reactions of the mesenteric remnants are particularly conspicuous in *Henricia*, where the mesenteries are normally discontinuous and web-like; here, one of the earliest internal events leading to caecal regeneration involves the formation, from these tattered strands, of the continuous, double-mesothelial sheets that join in pairs to constitute the mesenteric tunnels. The proximal portions of these tunnels, with the mesenchymal elements enclosed between their mesothelial layers, are in place and in readiness by the time the initial outgrowths from the proximal stumps of the caeca begin. The rod of cells advancing distally into the ray from the stump derives guidance and support from the mesenteric tunnel; further, it appears highly likely that at least some of the histological components of the regenerating caecum may originate in, or pass through, the mesenchyme filling the space between the mesothelial layers of the tunnel.

FIGURES 24, 25, 26. Progressively more distal levels of eight-week regenerate. Above the tubular regenerate in Figure 24 the mass of coelomocytes trapped between the mesenteries is in contact with the subepithelial mesenchyme and may be contributing cells to the regenerate. Conditions at the far distal levels in the eight-week specimen are comparable to those found more proximally in younger regenerates. All PTA hematoxylin. 460 \times .

The cause and possible significance of the marked hypertrophy of the peritoneum in regions adjacent to the mesenteric tunnels, and the nature and source of the cytoplasmic spherules with which the hypertrophied cells are packed, remain obscure. The development of the hypertrophy follows soon after operative removal of the caeca, but it may be related to the processes of healing and repair of the incision in the body wall rather than to regenerative changes leading to replacement of the caeca. The simple experiment which might shed light on this point has not been performed. In either case, two alternative explanations suggest themselves to account for the accumulation of cytoplasmic spherules in the peritoneal cells. Perhaps the spherules represent condensed remnants of digested tissue fragments, debris, necrotic material, and the like taken into the peritoneal cells by phagocytosis and held here either for eventual elimination or for ultimate utilization in the processes of repair. Alternatively, they may represent nutritional reserves mobilized and concentrated in the peritoneal cells nearest the sites of repair and regeneration. No attempts at precise characterization have been made, but the spherules are evidently neither fatty nor of predominantly polysaccharide nature; their general staining behavior resembles that of some proteins. Spherule-packed peritoneal cells are frequently incorporated into the mesothelial sheets forming the mesenteric tunnels. At early stages this is particularly noticeable in proximal areas near the severed caecal stumps, where degenerative changes in the caecal epithelium seem to be occurring. Later, peritoneal hypertrophy has usually subsided in the proximal regions where regeneration of the caeca is well advanced, but it persists in the more distal areas in association with earlier regenerative phases.

The close relationship which exists in *Henricia* between regenerating caeca and the remnants of the mesenteries suggests comparison with a parallel situation previously described by several investigators studying visceral regeneration in various sea-cucumbers. In all the holothurians studied, replacement of the gut always involves an initial thickening of the free edge of the mesentery. In *Stichopus*, studied by Bertolini (1930) and by Dawbin (1949), the thickening develops at a practically uniform rate along the length of the mesentery and results, according to Dawbin, from an increase in the number of mesenchyme cells enclosed between the mesothelial sheets which have fused at the mesentery edge, where the mesenchyme gradually forms a solid, cordlike swelling. In *Thyone*, Kille (1935, p. 93) states, without giving additional histological details, that sections of the thickened edge of the mesentery show it to be "... a solid rod of connective tissue covered by a much thickened mesothelium." Whether this thickened mesothelium is like that encountered in *Henricia* cannot be determined from this description. In various species of *Holothuria*, Bertolini (1932) and Kille (1936) have described early thickening of the mesentery edge involving hyperplasia of the mesenchyme. In all the sea-cucumbers studied, it is within this rodlike swelling at the mesentery edge that the lumen of the new gut forms, but there is a surprising divergence in the processes leading to its formation in the various genera. In *Stichopus*, Bertolini and Dawbin agree that the lumen develops by extension and fusion of clefts in the mesenchymal thickening, and that its lining forms by later differentiation of mesenchymal cells. In *Thyone*, and even more clearly in *Holothuria*, the lumen of the new gut does not develop directly in the mesenchymal thickening at the mesentery edge; this thickened edge

is secondarily invaded by tubular ingrowths from both ends. In *Thyone*, which eviscerates orally ("anteriorly"), only the posterior tongue of invading cells is continuous with a remnant of the original gut; the anterior ingrowth stems from a portion of the newly regenerated lantern. In *Holothuria*, which eviscerates aborally, both of the ingrowing tubules originate from remnants of the old digestive tract. The lumens of these tubules become continuous where the ingrowths meet and fuse, and the origin of the lining epithelium is clearly different from that found in *Stichopus*.

This contrast in regenerative processes has been recognized by several students of holothurian gut regeneration and has been most recently discussed by Dawbin (1949). What is of particular interest in the present connection is the general similarity between the process of gut regeneration in *Holothuria* and that now described for the replacement of pyloric caeca in *Henricia*. The differences in detail that do exist can be related to differences in the structure of the mesenteries in the two forms (single in *Holothuria*, paired in *Henricia*), and perhaps more particularly to the fact that in the sea-star we are dealing only with radial blind pouches of the gut rather than, as in the holothurian, with the entire axial portion of the digestive tract. But the replacement of the pyloric caecum in *Henricia* follows the same sequence of events as that displayed in the replacement of the gut in *Holothuria*: fusion of mesothelia at the free edge of the mesentery, followed by thickening of the mesenchyme enclosed here; invasion of the mesenchymal rod thus formed by tongues of cells advancing from whatever stumps of the original structure remain, a lumen then developing inside the ingrowth; and, finally, differentiation of a normal lining epithelium and of the subepithelial components of the organ.

The rod or tongue of tissue growing outward from the stump of the pyloric duct in *Henricia* advances in such a way as to suggest that an active center of cell proliferation must be present in the regenerating organ. Further, the gradient of differentiation in the newly forming caecum, running from tip to base, indicates that the source of the cells must lie at or near the tip itself, growing distally and leaving new cells behind it to undergo differentiation. Surprisingly, however, no zones of mitotic activity have been found in any of the regenerating caeca studied, although such areas have been carefully sought. Perhaps cell divisions in this tissue occur in cycles, and my observations have by chance missed what is in fact occurring. Alternatively, there is the possibility that the regenerating tissue grows not through the proliferation of its own cells but by the incorporation of amoebocytes recruited from the myriads wandering in the mesenchyme throughout the body. The presence of an abundance of large amoebocytes in the mesenchyme of the mesenteric tunnels has been noted, and it may be that one of the important functions of the mesenteries is to form a bridge for the passage of such cells from the body wall into the region of the advancing tubular regenerate. In *Stichopus*, Dawbin (1949) describes numerous large amoebocytes passing by way of the mesentery into the regenerating gut, and accumulations of these cells form the thickening at the mesentery edge. Only in later stages, after the formation of the lumen, does mitotic activity begin to increase the numbers of cells destined to form the lining epithelium.

This account by Dawbin, it should be noted, is the only treatment of regeneration in echinoderms in which I have found specific reference to cellular proliferation

in the regenerating tissue, and the situation in *Stichopus* is so different from that in other holothurians, and in asteroids, that it may present no valid basis for comparison. It would be interesting to know the source of cells making up the tongues of tissue invading the mesenteries of *Holothuria*, but Bertolini's description (1932) unfortunately fails to make clear whether mitotic activity is involved. Turning from visceral regeneration to the more familiar and presumably better understood matter of parietal regeneration in asteroids, the account by Nusbaum and Oxner (1915) of regeneration in *Echinaster* describes histological details of wound healing and the reconstitution of muscular and skeletal elements. Outlining such events as dedifferentiation of specialized structures, phagocytosis of debris, and the like, the authors conclude that the principal processes involved in regeneration depend upon the mobilization, incorporation, and differentiation of amoebocytes. They apparently assign no role to cellular proliferation, and if they observed it at all this fact is not mentioned.

Obviously, problems of regeneration in asteroids, both visceral and parietal, require further study with attention to histological details and with more refined methods; equally obviously, the available evidence is too meager to form the basis of firm conclusions. But it seems at least admissible, and in view of the information available for other regenerating echinoderms not unreasonable, to suggest that in the regenerating pyloric caecum of *Henricia* there is no zone of growth in the sense of a localized distal region of mitotic activity. Until further studies now in progress to elucidate this point can be completed, it is provisionally concluded that the advance of the undifferentiated tip of the regenerate may occur by progressive accumulation and addition of amoebocytes moving through the mesenchymal layer. Further conjecture at the moment seems unwarranted.

It is of interest to note that Tiedemann's pouch does not form in the regenerating caecum by outgrowth on a broad front from the stump of what has been termed Tiedemann's duct (Anderson, 1960). Rather, in its early stages the caecal regenerate is simply tubular and even at eight weeks forms a simple cylinder in its younger, more distal portions. As has been noted, however, even at four weeks the proximal portion has become much deeper in cross-section, and by the eighth week there are histological indications in the floor of the basal region suggesting that differentiation of the current-producing areas of the epithelium has begun. The localization and concentration of apparently active zymogen cells in the aboral epithelium of the regenerate is most conspicuous, and the contrast between roof and floor gives a clear forecast of the functional differences to be found in the finished organ. It is clear, however, that Tiedemann's pouch arises by progressive differentiation of the floor of the tubular regenerate. The cytological details of the transformation of undifferentiated epithelial cells into such highly specialized elements of the normal epithelium as zymogen cells, mucous gland cells, and the like remain to be described.

SUMMARY

1. Regeneration of pyloric caeca has been studied grossly and histologically in a series of specimens sacrificed one, two, three, four, six, and eight weeks following operative removal of the caeca by way of a median longitudinal incision through the aboral body wall of one ray.

2. After healing of the incision, which is fairly complete at the close of the second week, the cut stumps of the caeca are found to have healed over. The original web-like suspensory mesenteries have become continuous mesothelial sheets and have fused in pairs at their free edges to form mesenteric tunnels leading outward into the ray. The parietal peritoneum has become conspicuously hypertrophic, its normally flattened cells now tall and filled with deeply-staining cytoplasmic spherules.

3. During subsequent weeks one or both of the mesenteric tunnels may be invaded by an outgrowth from the central stump of the caeca, the outgrowing tongue of cells pushing through the mesenchymal thickening at the summit of the tunnel enclosed between the mesothelial layers. During early weeks one outgrowth usually lags behind the other; in later stages the two are more nearly equal in length and development. The tip of the outgrowth consists of a rod of large, undifferentiated cells sharply marked off from the surrounding mesenchyme. A short distance behind the tip a lumen develops simply as a cleft in the packed cells of the cylindrical regenerate. Nearer the base, the cells are seen to have undergone rearrangement to form a more regular lining, composed of taller cells showing the beginnings of a brush border and flagella. At all stages the outgrowth presents a regular gradient of differentiation between tip and base, the cells forming the tip being undifferentiated and young while those nearer the base show a gradual increase in degree of differentiation. At later stages this culminates, basally at least, in the formation of an essentially normal epithelium, provided with mucous gland cells and zymogen cells. Subepithelial components, such as the characteristic muscular and connective-tissue layers, are slower to form but are in evidence at the base of the regenerate by the eighth week. The normal marked distinction between oral and aboral parts of the caecum begin to be suggested also by the eighth week; it is apparent that Tiedemann's pouch will form not by outgrowth along a broad front from its remnant stump but by specializations in the floor of the tubular caecal regenerate.

4. The process of regeneration in the pyloric caecum differs in at least one important respect from that involved in replacement of the parietal parts of a regenerating ray. In the regeneration of the entire ray, the highly differentiated distal tip with its sensory specializations forms first and precedes the more proximal, less differentiated areas as the ray elongates. By contrast, in the caecal outgrowth there is clearly no precociously differentiated tip region; the tip is obviously the youngest, least-differentiated portion. The sequence of events in regeneration of the pyloric caecum resembles to a degree that which has been described for replacement of the digestive tract following evisceration in *Holothuria*.

5. A particularly puzzling aspect of the regenerative process involves the fact that no zone of mitotic activity has been found in the caecal outgrowth, although such a zone might be expected to lie near the advancing tip of the regenerate. This raises the question as to the source of cells in the newly forming caecum, and it is suggested that the cells may come not from proliferation but from recruitment and incorporation of amoebocytes gathering in the mesenchymal layer through which the regenerate grows. A more general question is raised concerning the role of cell proliferation in other cases of regeneration in echinoderms; only in the somewhat atypical case of gut-replacement from mesenchyme in the

sea-cucumber *Stichopus* is there explicit description of mitotic activity as a feature of regeneration.

LITERATURE CITED

- ANDERSON, J. M., 1960. Histological studies on the digestive system of a starfish, *Henricia*, with notes on Tiedemann's pouches in starfishes. *Biol. Bull.*, **119**: 371-398.
- BERTOLINI, F., 1930. Rigenerazione dell'apparato digerente nello *Stichopus regalis*. *Pubbl. Staz. Zool. Napoli*, **10**: 439-447.
- BERTOLINI, F., 1932. Rigenerazione dell'apparato digerente nelle Holothuria. *Pubbl. Staz. Zool. Napoli*, **12**: 432-443.
- DAWBIN, W. H., 1949. Auto-evisceration and the regeneration of viscera in the holothurian *Stichopus mollis* (Hutton). *Trans. Roy. Soc. New Zealand*, **77**: 497-523.
- FERGUSON, J. C., 1960. The nature of the connective tissue of the body wall, retractor harness, and cardiac stomach of the starfish, *Asterias forbesi*. *Anat. Rec.*, **138**: 348.
- HYMAN, L. H., 1955. The Invertebrates. Volume IV, Echinodermata. New York: McGraw-Hill Book Co.
- KILLE, F. R., 1935. Regeneration in *Thyone briareus* Lesueur following induced autotomy. *Biol. Bull.*, **69**: 82-108.
- KILLE, F. R., 1936. Regeneration in holothurians. *Ann. Rept. Tortugas Laboratory, Carnegie Inst. Wash., Yearbook* **35**: 85-86.
- NUSBAUM, J., AND M. OXNER, 1915. Zur Restitution bei dem Seestern *Echinaster sepositus* Lam. *Zool. Anz.*, **46**: 161-167.
- SCHAPIRO, J., 1914. Ueber die Regenerationserscheinungen verschiedener Seesternarten. *Arch. f. Entw.*, **38**: 201-251.
- ZIRPOLO, G., 1921. Rigenerazione delle braccia di *Asterina gibbosa*. *Pubbl. Staz. Zool. Napoli*, **3**: 93-163.